

## Protective effect of some antioxidants on the brain of adult male albino rats, *Rattus rattus*, exposed to heavy metals

E. A. Amal\* and H. M. Mona

Radioisotopes Department, Atomic Energy Authority, Egypt.

\*Corresponding author

Adult male albino rats were exposed to 100 mg/L of lead acetate or 100 mg/L sodium arsenate in drinking water for 3 and 6 weeks, lead and arsenic inhibit cholinesterase activity after both time intervals, with percentage reached 23% and 25% in lead and arsenic after 6 weeks, respectively. The results revealed that lead or arsenic leading to increase in relative brain weight in most of the experimental period. Using antox, (an antioxidant contains three supplementary nutritional vitamins A, C and E with rare element selenium) with lead or arsenic led to an improvement of serum cholinesterase activity in rats and also relative brain weight. Histological studies showed that lead and arsenic treated rats induced neuron injuries and change in brain cells. Rats treated with antox during administration of lead or arsenic repair some injuries of brain cells and neuron induced by lead or arsenic. Rats treated with both lead or arsenic and antox revealed an improvement in histopathological alteration induced by lead or by arsenic after 3 weeks and 6 weeks. This proved the effectiveness of antox that attributed to its antioxidant properties. In conclusion, heavy metals i.e. lead and arsenic proved severely neurotoxic and antox reduces the resulting damage probably due to its ability to neutralize free radicals that are generated by lead and arsenic.

**Key words:** Lead acetate, Sodium arsenate, Antox, Cholinesterase

Lead is a ubiquitous environmental and industrial pollutant that has been detected in almost all biological systems. Many investigations have been performed about the physiological, biochemical, and behavioral effects of this toxic elements in animals including disorders of central and peripheral nervous system, cardiovascular system, kidney, liver and reproductive system (Ping and Yueliang, 2002) brain has been shown to be more susceptible to the neurotoxic effects of lead (Ani *et al.* 2007 & Smith and Cass, 2007). In addition, lead exposure mainly affects cholinergic system by reducing acetylcholine release, uptake and turnover rates (Prasanthi and Reddy, 2006) lead also has been shown to reduce enzyme activity including AchE.

Arsenic is widely distributed in nature, being found in food, the soil, water and airborne particles; it derives from both natural and human activities (Ping and Yueliang, 2002). More than 80% of arsenic compounds are used to manufacture

products with agricultural applications such as insecticides, herbicides, fungicides and algicides (Tchounwou *et al.* 1999, National Academy of Science, 1997). Although food is usually the major source of arsenic exposure, most adverse effects have been associated with consumption of arsenic contaminated drinking water sources occupational of arsenic to human workers include vineyards, ceramics, glass making, smelting and refining of metallic ores (Tchounwou *et al.* 2004). The gastrointestinal tract of human and most experimental animals readily absorbs ingested inorganic arsenic (> 90%). Following absorption arsenic compounds through blood circulation are distributed in various tissues (blood, liver, kidney, lung and skin) (Mckinney, 1992).

Several studies have indicated that the toxicity of arsenic depends on the exposure dose, frequency and duration, biological species, age, gender as well as an individual susceptibilities, genetic and

nutritional factors (Tchounwon, 2001). Analyzing the toxic effects of arsenic is complicated because the toxicity varies according to its oxidation state, its solubility and many different inorganic and organic forms (Tchounwon, 2003). Their acute and chronic toxic effects involve many organs systems, including the central nervous system (CNS) (Anita and Paul, 2005), further indicated that acetylcholinesterase (AChE) activity in rats was inhibited in some regions of the brain following inorganic arsenic intake. A critical important nervous system enzyme that hydrolyzes the neurotransmitter acetylcholine (Nagaraju *et al.* 1994).

Chemical agents such as heavy metals, induce oxidative stress leading to generation of more free radicals and alteration in antioxidants or oxygen free radical scavenging enzyme (Tawfik 2005). The body creates free radicals and oxygen reactive species continuously; however, the antioxidants provide the body with protection against them. The antioxidants are either reactive chemicals such as vitamin E or specialized enzymes as catalase. The body produces enzymatic antioxidants but can not make the antioxidant chemicals (e.g. vitamin E, C and flavonoids), that protect the sites in the body that the enzymatic antioxidants can not reach (Haggag *et al.* 2002). (Prseton, 1991) mentioned that beta carotene (a carotenoid metabolic precursor to vitamin A), vitamin E, C and selenium (Sel) are involved in the overall cellular antioxidant defense mechanism.

Antox is an antioxidant contains three supplementary nutritional vitamins A, C and E with rare element selenium which essential for normal metabolic reactions. Selenium seems to reduce the toxicity of several heavy metals probably by forming inert selenid complex. Selenium is also known to provide protection from reactive oxygen species (ROS)-induced cell damage (Santamaria *et al.* 2003).

The present study was aimed to through more light on the effect of lead and arsenic on the central nervous system of adult male rats treated for three and six consecutive weeks. Serum cholinesterase activity and the ability of antioxidant (antox) to combat lead and arsenic toxicity were examined.

Histopathological changes in the brain of adult male rats after administration of either lead acetate or sodium arsenate via drinking water, with or without antox treatment after 3 and 6 weeks were also studied. The study was designed to evaluate the dangerous effects of chronic exposures to lead acetate and sodium arsenate as chemical substances that may pollutes the environment, causing severely problems for human health and animals. Also to investigates the important protective role of antioxidant (antox).

## MATERIALS AND METHODS

This study included a total number of seventy two male albino rats (*Rattus rattus*), weighing from 120 – 140 g. they were obtained from animal house of the National Research Center, Dokki, Giza. All animals were allowed to acclimatize for a week prior to initiating the experiment, they were freely fed on normal rodent pellets and clean water offered *ad libitum* throughout the adaptation period.

**Animals under investigation:** The rats were divided into 12 equal groups of 6 rats each as follows: the 1<sup>st</sup> and 2<sup>nd</sup> groups served as control received *ad libitum* food and water for three and six weeks.

The 3<sup>rd</sup> and 4<sup>th</sup> groups received 100 mg/L of lead as lead acetate [(Cl<sub>3</sub>COO)<sub>2</sub> Pb 3H<sub>2</sub>O] was dissolved in drinking water for three and six weeks.

The 5<sup>th</sup> and 6<sup>th</sup> groups received a daily oral dose of antioxidant (10 mg/kg) body weight for three and six weeks.

The 7<sup>th</sup> and 8<sup>th</sup> groups received 100 mg/L lead in drinking water and antox (10 mg/kg body weight) for three and six weeks.

The 9<sup>th</sup> and 10<sup>th</sup> groups received arsenic as sodium arsenate (Na<sub>2</sub> HASO<sub>4</sub>. 7H<sub>2</sub>O) 100 mg/L dissolved in drinking water for three and six weeks.

The 11<sup>th</sup> and 12<sup>th</sup> groups received a daily oral dose of 10 mg/kg antox and 100 mg/L As in drinking water for three and six weeks.

Antox (antioxidant drug composed of selenium, vitamin A acetate, ascorbic acid and vitamin E) was suspended in distilled water and administered by stomach tube.

The treated rats and the control groups were sacrificed using slight ether

anesthesia. Blood samples were collected directly by cardiac puncture. Serum cholinesterase was quantitated using cholinesterase kit according to (Ellman *et al.* 1961) derived from Boehringer Company. Brain of all dissected animals were carefully removed, washed in an isotonic solution, blotted on a filter paper, weighing and then putted in a suitable fixative (10% normal formaline). Paraffin section of 6  $\mu\text{m}$  thickness was cut and stained with hematoxylin (HX) and eosin (E) for the histological studies in order to follow up the destruction in the tissues and cells of brain. This procedure was carried out at Faculty of Veterinary Medicine, Cairo University.

**Statistical analysis:** The statistical significance of the mean values between groups was performed using Microsoft Excel 2003 software program.

## RESULTS AND DISCUSSION

The dose level of 100 mg/L lead acetate in drinking water significantly inhibit cholinesterase activity after 3 and 6 weeks, by the percentage decrease reached 18.55% and 22.65%, respectively (Table 1). The present results are in agreement with those of Ani *et al.* (2007), who reported that intra peritoneally administration of Pb (13.5 mg/kg body weight) for 2 weeks reduced the activity of AchE in different brain region.

The toxic effect of lead may be due to the binding to the metallothionein (MT) that is rich in sulphhydryl groups implicated in zinc and copper homeostasis (Ping and Yueliang, 2002). Calcium has been shown to be required for physiological functions including signal transduction and neurotransmission which is also affected by lead. Lead also has been shown to reduce enzyme activity including AchE and  $\text{Na}^+/\text{K}^+$  ATPase activity, although the exact mechanism by which the enzyme activity is altered remains to be cleared but lead probably changes the binding kinetics of  $\text{Na}^+/\text{K}^+$  ATPase activity that plays an original role in linking the extracellular signals to intracellular at the neurons and also affects cholinergic transmission (Yallapragadap *et al.* 2003).

Cholinesterase activity in serum of rats treated with 100 mg/L sodium arsenate in drinking water significantly inhibited after 3

and 6 weeks as compared to the control groups represented 11% and 25.53%, respectively (Table 2). Anito and Paul (2005) reported that arsenic trioxide was intraperitoneally administered to the rats at the doses of 5, 10, 15 and 20 mg/kg body weight, significantly inhibit the activity of cholinesterase indicating a gradual decrease in acetylcholinesterase activity with the increasing doses of arsenic. These findings indicate that acetylcholinesterase is a candidate biomarker for arsenic-induced neurotoxicity in Sprague-Dawley rats (Tripathi *et al.* 1997). Our results agree with the previous studies. Further indicated that acute toxicity of arsenical pesticides manifests as a cholinergic crisis with excessive glandular secretion, altered mental status, weakness, myasthenic-like syndrome, peripheral neuropathies, neuropsychiatric abnormalities and extrapyramidal disorders (Rusyniak and Nanagas, 2004).

In present study, relative brain weights were significantly increased after 3 and 6 weeks of lead administration (Table 3) and also after arsenic dose for 3 and 6 weeks (Table 4) regard to relative brain weight there were a significant increased in both groups. In contrast to our investigation in adult male rats, the work in developing rats was previously reported by Ferris and Cragg (1984), who observed that, weekly injections of tetramethyl lead (TML), administered from first week after conception until post-natal day 6 significantly decrease in brain weight and significant increase in body/brain weight ratio. In this respect Chunxiang *et al.* (2006) studied the effect of high arsenic administration on brain development. They reported marked decrease in brain weight of exposed rats to arsenic after 30 days in comparison with normal control, while after 90 days of arsenic exposure the brain weight were more or less than normal control.

Antox is a multivitamin compound (ascorbic acid, c vitamin A acetate, vitamin E and selenium), the protective effect of these vitamins that represent strong antioxidants, free radical scavenging activity (Hawzzen and Maisaa, 2007).

The data recorded in (Table 1) elucidated that the treatment with antox at dose level of 10 mg/kg body weight at the

same time with lead administration induced gradual improvement serum ChE activity to reach around normal control value after 6 weeks in comparison with control group.

**Table 1: Effect of lead as lead acetate administered in drinking water (100 mg/L) and lead with antox (10 mg/kg body weight) on cholinesterase of adult male rats.**

Time	Groups	Control	Lead acetate	Antox	Lead acetate + Antox
3 weeks	Mean	433.16	352.80	416.10	393.00
	± S.E.	± 14.39	±10.46***	± 19.30	± 11.98
	% Change		-18.55	-3.90	-9.27
6 weeks	Mean	423.83	327.83	415.30	432.00
	± S.E.	± 12.13	± 16.02	± 37.50	± 15.86
	% Change		-22.65	-2.00	1.92

\*P < 0.05: Significant , \*\*\*P < 0.01: Highly significant

**Table 2: Effect of arsenic as sodium arsenate administered in drinking water (100 mg/L) and arsenic with antox (10 mg/kg body weight) on cholinesterase of adult male rats.**

Time	Groups	Control	Sodium arsenate	Antox	Sodium arsenate + Antox
3 weeks	Mean	433.16	385.50	416.10	446.50
	± S.E.	± 14.39	± 5.50***	± 19.30	± 9.82
	% Change		11.00	3.90	3.0
6 weeks	Mean	423.83	315.60	415.30	442.67
	± S.E.	± 12.83	± 12.27	± 37.50	± 8.50
	% Change		25.53	2.00	4.40

**Table 3: Effect of lead acetate administered in drinking water (100 mg/L) and/or lead with antox (10 mg/kg body weight) on relative brain weight of adult male rats.**

Time	Groups	Control	Lead acetate	Antox	Lead acetate + Antox
3 weeks	Mean	0.60	0.81	0.75	0.76 ± 0.02***
	± S.E.	±0.02	±0.02***	±0.02***	
6 weeks	Mean	0.63	0.68	0.68	0.70
	± S.E.	±0.02	±0.02	±0.02	± 0.01*

\*P < 0.05: Significant , \*\*\*P < 0.01: Highly significant

**Table 4: Effect of sodium arsenate administered in drinking water (100 mg/L) and/or lead with antox (10 mg/kg body weight) on relative brain weight of adult male rats.**

Time	Groups	Control	Sodium arsenate	Antox	Sodium arsenate + Antox
3 weeks	Mean	0.60	0.92	0.75	0.82
	± S.E.	±0.02	±0.04***	±0.02***	± 0.042***
6 weeks	Mean	0.63	0.80	0.68	0.78
	± S.E.	±0.02	±0.02***	±0.02	± 0.06

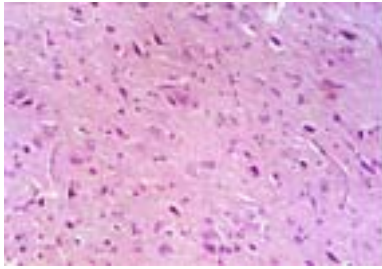
\*P < 0.05: Significant , \*\*\*P < 0.01: Highly significant

In addition, antox greatly ameliorate the toxic effect of arsenic on ChE activity which was noticeable tendency towards normal control values (Table 2). These results are coincide with results of (Hawazen and Maisaa, 2007) who reported that, the antioxidant antox led to an improvement in both histological and biochemical alteration of rats induced by toxic herbicide paraquat. (Sanali et al. 2006) stated that, the ameliorative potential of selenium on arsenic mediated inhibition of AchE revealed a positive role of selenium (Se), especially when Se preceded As<sub>2</sub>O<sub>3</sub>

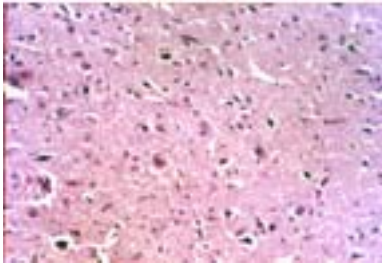
treatment in (*Channa Punctatus* Bloch fish) either *in vitro* or *in vivo*.

**Histological study:** Investigation of brain sections of control rats dissected after 3 and 6 weeks (figs. 1 & 2) respectively showed normal neurons cells. Brain section of rats received 100 mg/L lead acetate in drinking water for 3 weeks (Figs. 3a and 3b) showed pyknosis of neurons (fig. 3b) associated with focal gliosis. In addition after administration of lead for 6 weeks induced focal cerebral hemorrhage as shown in (fig. 4a), pyknosis of neurons (figs. 4b & 4c) associated with focal gliosis (fig. 4b) and neuronophagia (fig.

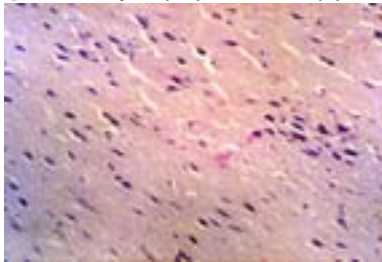
4c). Brain sections of rats treated with 10 mg/kg body weight antox either for (3ws or 6ws) showed normal neuron cells (figs. 5 & 6), respectively. Examined brain of rats



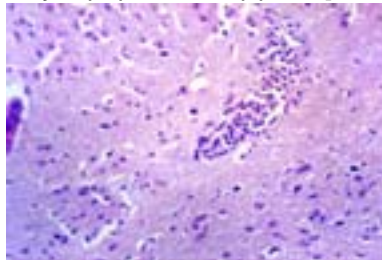
**Fig : 1** Section of control brain rat dissected after (3 weeks) [Haematoxylin (Hx) and eosin (E) x 200]



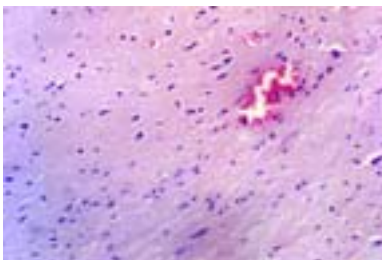
**Fig : 2** Section of control brain rat dissected after (6 weeks) [Haematoxylin (Hx) and eosin (E) x 200]



**Fig: 3.a** Brain of rat treated with toxic lead acetate showing pyknosis of neurouns (3 weeks) [Haematoxylin (Hx) and eosin (E) x 200]

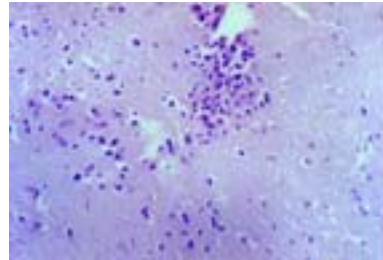


**Fig (3.b):** Brain of rat treated with lead acetate (3 weeks) showing pyknosis of neurons associated with focal gliosis. [Haematoxylin (Hx) and eosin (E) x 200]

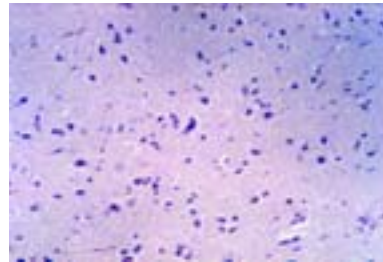


**Fig (4.a):** Brain of rat treated with lead acetate (6 weeks) showing focal cerebral hemorrhage. [Haematoxylin (Hx) and eosin (E) x 200]

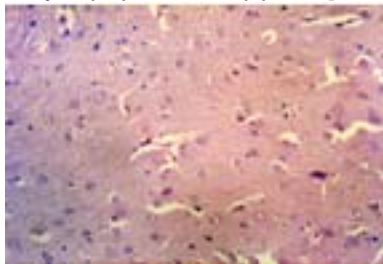
treated with lead and antox after 3 weeks or 6 weeks showed no histopathological changes except pyknosis of some neurons (figs. 7 & 8).



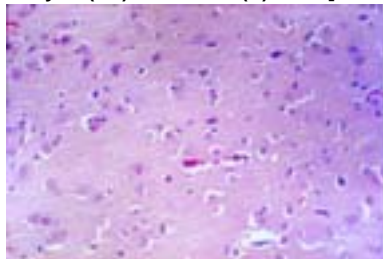
**Fig (4.b):** Brain of rat treated with lead acetate (6 weeks) showing pyknosis of neurons associated with focal gliosis. [Haematoxylin (Hx) and eosin (E) x 200]



**Fig (4.c):** Brain of rat treated with lead (6 weeks) showing pyknosis of neurons and neuronophagia [Haematoxylin (Hx) and eosin (E) x 200]



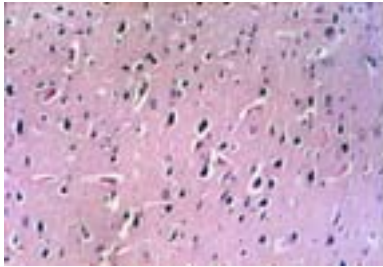
**Fig (5):** Brain of rat treated with Antox (3 weeks) showing no histopathological changes [Haematoxylin (Hx) and eosin (E) x 200]



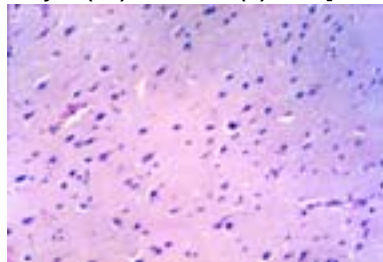
**Fig (6):** Brain of rat treated with Antox (6 weeks) showing no histopathological changes [Haematoxylin (Hx) and eosin (E) x 200]

Meanwhile, brain of rats treated with 100mg/L sodium arsenate after 3 weeks revealed pyknosis of neurons and neuronophagia (fig. 9a) as well as focal cerebral gliosis (fig. 9b). Brain of rats treated with sodium arsenate after 6 weeks showed congestion of cerebral blood vessel (fig. 10a), pyknosis of neurons as well as focal

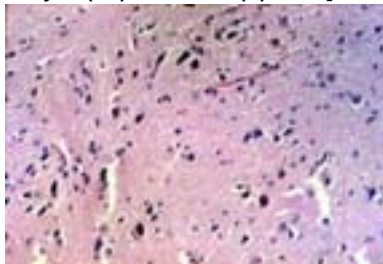
cerebral hemorrhage (fig. 10b). Brain of rats treated with sodium arsenate and antox (3 weeks) showed slight cellular edema (fig. 11).



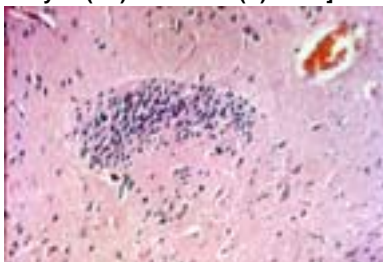
**Fig (7):** Brain of rat treated with lead acetate + Antox showing pyknosis of some neurons. [Haematoxylin (Hx) and eosin (E) x 200]



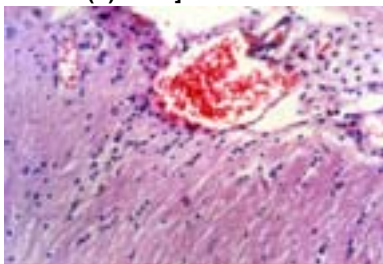
**Fig (8):** Brain of rat treated with lead acetate +Antox (6 weeks) showing pyknosis of neurons. [Haematoxylin (Hx) and eosin (E) x 200]



**Fig (9.a):** Brain of rat treated with sodium arsenate showing pyknosis of neurons and neuronophagia. [Haematoxylin (Hx) and eosin (E) x 200]

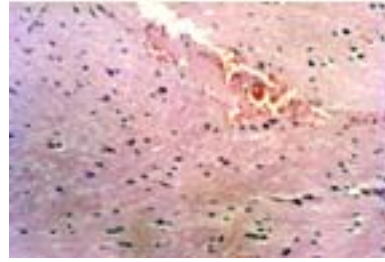


**Fig (9.b):** Brain of rat treated with sodium arsenate (3 weeks) showing focal gliosis. [Haematoxylin (Hx) and eosin (E) x 200]

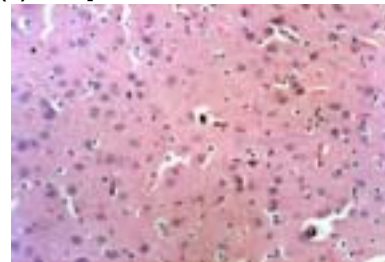


**Fig (10.a):** Brain of rat treated with toxic sodium arsenate (6 weeks) showing congestion of cerebral

blood vessel. [Haematoxylin (Hx) and eosin (E) x 200]

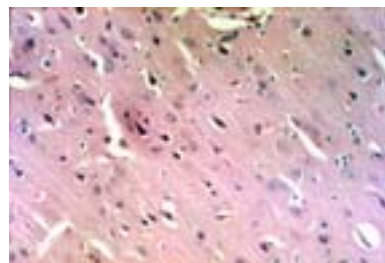


**Fig (10.b):** Brain of rat treated with sodium arsenate (6 weeks) showing pyknosis of neurons as well as focal cerebral hemorrhage. [Haematoxylin (Hx) and eosin (E) x 200]



**Fig (11):** Brain of rat treated with sodium arsenate + Antox (3 weeks) showing slight cellular edema. [Haematoxylin (Hx) and eosin (E) x 200]

Moreover, brain of rats treated with arsenic and antox (6 weeks) showed some histopathological appearance such as pyknosis of some neurons (fig. 12).



**Fig (12):** Brain of rat treated with sodium arsenate + Antox (6 weeks) showing pyknosis of some neurons. [Haematoxylin (Hx) and eosin (E) x 200]

It can be concluded from the histological studies that lead or arsenic induced some changes in brain structure of the treated adult male rats after 3 weeks while after 6 weeks caused serious damage and changes in brain cell structures. The histological findings are in agreement with (Engin Deveci, 2006), who reported that when rats received lead acetate at dose of 500 ppm in their drinking water for 60 days showed degeneration in some of the neuron cells, in the lumens of the blood vessels, dilation, hemorrhagia and free floating

erythrocytes were observed in the brain cortex. Ultra-structural changes were revealed in the form of vacularisation of cell cytoplasm and degeneration in mitochondria, in the perinuclear cytoplasm, electron dense inclusion bodies were detected, and dilation were in the endoplasmic reticulum. (Pardeep and Bimla, 2003) observed that after lead treatment at dose level of 50 mg/kg body weight rat, transverse sections of cerebrum showed degeneration of neurons. Disruption normal arrangement of cell layers was seen. Cells were bigger in size with large vascular spaces around them. Lead treatment for 8 weeks also was enough to disrupt the normal arrangement of cellular layer of cerebellum. Large spaces in between purkinje cell layer and granular layer were seen. On the other hand, rats treated with both lead or arsenic and antox revealed an improvement in histopathological alteration induced by lead or by arsenic after 3 weeks and 6 weeks. This proved the effectiveness of antox that attributed to its antioxidant properties.

In conclusion, heavy metals i.e. lead and arsenic proved severely neurotoxic and antox reduces the resulting damage probably due to its ability to neutralize free radicals that are generated by lead and arsenic. This study elucidated the protective role of antox against heavy metal toxicity.

#### ACKNOWLEDGEMENT

Thanks to Prof. Ass. Kawkab Abdel-Aziz Ahmed, assistant professor of pathology, Faculty of Veterinary Medicine, Cairo University for her helpful guidance in the histological study of this work.

#### REFERENCES

- Ani M., Moshtaghie AA and Aghadavood M, 2007. Protective effects of selenium and zinc on the brain acetylcholinesterase activity in lead intoxicated rat. *Research in Pharmaceutical Sciences* 2: 80-84
- Anita K. Patlolla and Paul B. Tchounwou. 2005. Serum acetyl cholinesterase as a biomarker of arsenic induced neurotoxicity in Sprague dawley rats. *Int. J. Environ. Res. Public Health*. 2(1): 80 – 83
- Chunxiang Wu, Xinli Gu, Yaming Ge, Jianhai Zhang, Jundong Wang Shonxi. 2006. Effect of high fluoride and arsenic on brain biochemical indexes and learning-memory in rats. *Research Report Flouride*, 39 (4): 274 – 279
- El-Kholy NM, Samar KK, Ayman B and Mohamed AA, 1999. *The Egyptian Journal of Biochemistry* 17(1): 189
- Ellman GL *et al.* 1961. Measurement of time required for a  $\Delta A$  of 0.100. *Biochem. Pharmacol.* 7: 88
- Engin Deveci, 2006. Ultrastructural effects of lead acetate on brain of rats. *Toxicology and Industrial Health* 22(10): 419 – 422
- Ferris NJ and Cragg BG, 1984. Organic lead and histological parameters of brain development. *Acta Neuropathologic Journal*. Springer Berlin Heidelberg, 63 (4).
- Hawazzen A Lamfon and Maisaa M Al-Rawi, 2007. Effect of antox on paraquat-induced histological and biochemical changes in kidney of albino rats. *Journal of Applied Sciences* 3 (10): 988 – 993).
- Haggag AM, Abu-Taleb AM and El-Abiad NM, 2002. The role of Antox (Vitamins A, E, C and Selenium ) in carbon tetrachloride-induced hepatotoxicity in rats. *Arab journal of nuclear science and applications*, 35(1) 339-345
- Mckinney JD, 1992. Metabolism and disposition of inorganic arsenic in laboratory animals and humans. *Environ. Oeochem. Health* 14: 43 – 48
- Nagaraju TN, Desiraju T, 1994. Effects on operant learning and brain acetylcholinesterase activity in rats following chronic inorganic arsenic intake. *Human Exper. Toxicol.* 13 : 353 – 356
- National Academy of Science. Arsenic; Washington, D.C. (1977).
- Pardeep Sidhu, Bimla Nehru, 2003. Lead intoxication: histological and oxidative damage in rat cerebrum and cerebellum. *The Journal of Trace Elements in Experimental Medicine* 17(1): 45 – 53
- Ping-Chi H and Yueliang M, 2002. Antioxidant nutrients and lead toxicity. *Toxicology* 180: 33 – 44
- Prasanthi R, Reddy G. Calcium or zinc supplementation reduced lead toxicity. *Nutr. Res.* 26: 537–545 (2006).

- Preston AM, 1991. Cigarette Smoking-nutritional Implications. *Prog. Food. Nutr. Sci.* 15(4): 183-217.
- Rusyniak DE and Nanagas KA, 2004. Organophosphate poisoning semin. *Neurol.* 24 (2): 197-204
- Santamaria A, Sanchez A and Roman B, 2003. Protective effects of antioxidant selenium on quinalinic acid induces neurotoxicity in rat. *J. Neurochem.* 86: 479 – 488
- Smith M and Cass W, 2007. Oxidative stress and dopamine depletion in an intrastriatal. 6-hydroxy dopamine model of Parkinson's disease. *J. Neurosci.* 144:1057-1066
- Sonali Roy, Asamanja chattroraj and Shelley Bhattacho, 2006. Arsenic—induced changes in optic tectal histoachitecture and acetylcholinesterase-acetylcholine profile in channa punctuatus amelioration by selenium. *Comparative. Biochemistry and Physiology Part C: Toxicology & Pharmacology*, 144 (1)
- Steven G. Newzealand Science, monthly 70 (6), 6 (1999).
- Tchounwou PB, Centeno JA, and Patlolla AK. 2004., Arsenic toxicity, Mutagenesis and carcinogenesis. A health risk assessment and management approach. *Mol. Cell. Biochem.* 255: 47-55
- Tchounwou, P.B; Patlolla, A.K; Centeno, J.A. Carcinogenic and systemic health effects associated with arsenic exposure. A critical Review. *Toxicol. Pathol.*, 31 (6): 575 – 88 (2003).
- Tchounwou PB, Wilson BA and Ishaque A, 1999. Important considerations in the development of public health advisories for arsenic and arsenic containing compounds in drinking water. *Rev. Environ. Health.* 14:1-19
- Tchounwou PB, Wilson B.A, Ishque A and Schneider J, 2001. Atrazine potentiation of arsenic trioxide induced cytotoxicity and gene expression in HepO2 cells. *Mol. Cell. Biochem.* 222: 49 – 59
- Tripathi N, Kannan GM, Pant BP, Jaiswal DK, Maphotra PR and Flora SJS, 1997. Arsenic-induced changes in certain neurotransmitter levels and their recoveries following chelation in rat whole brain. *Toxicol. Lett.*
- Tawfik SMF, 2005. Daconate herbicide toxicity on lipid peroxidation and antioxidant enzymes in blood of rats. *Isotope and Rad. Res.* 37, 2, 335-344 I
- Yallapragada P, Butler J and Kumar B, 2003. In vitro effect of lead on Na, K ATPase activity in different regions of adult rat brain. *Drug Chem. Toxicol.*, 26: 117-124.