



Available online freely at [www.isisn.org](http://www.isisn.org)

# Bioscience Research

Print ISSN: 1811-9506 Online ISSN: 2218-3973

Journal by Innovative Scientific Information & Services Network



RESEARCH ARTICLE

BIOSCIENCE RESEARCH, 2020 17(4): 2688-2694.

OPEN ACCESS

## Assessment of the Pituitary Bright Spot Phenomena Among Sudanese Population Using MRI

Shayma Hamed<sup>1</sup>, Ayad CE<sup>1</sup>, Awadia Gareeballah<sup>2,3</sup>, Alaa Ibrahim<sup>5,6</sup>, Rana A Eisa<sup>4</sup>, E.Abdelrahim<sup>7</sup> and Moawia Gameraddin<sup>2</sup>

<sup>1</sup> Sudan university of science and technology, College of Medical Radiology Sciences, Khartoum, **Sudan**

<sup>2</sup>Department of Diagnostic Radiologic Technology, Faculty of Applied Medical Sciences, Taibah University, Al-Madinah Al-Munawarah, **Kingdom of Saudi Arabia**

<sup>3</sup>Faculty of Radiological Sciences and Medical Imaging, Alzaeim Alazhari University University, Khartoum -**Sudan**

<sup>4</sup> Colleges of Applied Studies and Community Services, Health Sciences Department, King Saud University Riyadh-KSA

<sup>5</sup> Department of Radiological Sciences, Al-Ghad International College, Tabouk, **Kingdom of Saudi Arabia**

<sup>6</sup> University of Medical Sciences and Technology, Khartoum, **Sudan**

<sup>7</sup> Taif University, College of Applied Medical Sciences, Radiological Department. **Kingdom of Saudi Arabia**

\*Correspondence: [rana.eisa@gmail.com](mailto:rana.eisa@gmail.com) Received 20-10-2020, Revised: 21-11-2020, Accepted: 22-11-2020 e-Published: 23-11-2020

A pituitary bright spot (PBS) is the normal phenomenon of hyperintensity area that appears on non-enhanced T1-weighted MRI (Magnetic Resonance Imaging) just posterior to the Sella turcica in the posterior pituitary. Variation in size may be difficult to differentiate from pathology (hemorrhage), so standard PBS measurement is essential. This study aims to assess the normal PSB and its dimensions in normal Sudanese adults using MRI. A cross-sectional study conducted in 120 Sudanese adult subjects (46 males and 74 females) underwent an MRI examination for the brain at Al Amal National Hospital and Yastabshiroon Umdorman medical center. Their age ranged between 20 to 60 years. General Electric Health Care (GE SIGNA EXCITE) 0.2T permanent magnet (open magnet) and 1.5T closed magnet, Philips medical system (intera) machines were used for the examination. Brain MRI excluded if there are any pituitary abnormality. MRI T1-weighted sagittal images were obtained to determine if there are bright spot phenomena, then the long axis, short axis along with the pituitary bright spot area were measured. Among the 120 cases, PBS appears in 54.2%. The mean long axis of PBS was  $4.50 \pm 1.26$  mm; the mean short axis was  $2.79 \pm 0.70$  mm. The males had a significantly larger spot size than females ( $P < 0.001$ ), No significant difference in spot measurements in different age group ( $p > 0.05$ ). The incidence of PBS is 54.2% in adult Sudanese with normal pituitary gland, dimensions were significantly different between males and females.

**Keywords:** Pituitary Bright Spot (PBS); Posterior Pituitary gland; Magnetic Resonance Imaging (MRI); T1- weighted MR images

### INTRODUCTION

MR imaging is an imaging modality of choice for assessing the pituitary gland, enables functional evaluation and morphologic diagnosis. The pituitary gland is composed of anterior and posterior lobes, which yield higher signal intensity

than the pons on T1- weighted MR images. In the neonatal period, specifically the age of two months and more. It was reported that the anterior lobe of the pituitary gland showed a progressive decrease in signal intensity compared to the posterior lobe, which reveals persistent high

signal intensity on MRI T1-weighted images in the normal adult gland. So, the posterior pituitary gland shows high signal intensity on T1-weighted MR images under normal conditions. (Lee et al., 2001, Wang et al., 2018, Hess and Dillon, 2012)

An area of T1 hyperintensity is normally seen in the posterior part of Sella turcica immediately anterior to dorsum Sella on MRI of the brain, called the pituitary posterior bright spot (PPBS), which act as an indicator of pituitary neural function completion. (Andronikou, van Toorn and Boerhout, 2009, Kilday et al., 2014)

PPBS is well-characterized and is thought to be correlated to membrane-bound secretory vesicles containing anti-diuretic hormone (ADH) in the neurohypophysis. The PPBS long axis ranged from 1.2 mm and 8.5 mm and has a short axis 0.4 mm and 4.4 mm in the individual with no pituitary abnormality. It appears bright because of the storage of a hormone synthesized by the hypothalamus called vasopressin in the posterior pituitary lobe. This hormone shortens the intensity of the T1 signal since it is linked with a macropoteic structure compound called vasopressin–neurophysin II– copeptin complex. The resultant focal spot of high signal intensity on MR images correlates with normal function and is observed where the vasopressin is stored generally in the posterior pituitary lobe. The pituitary gland is located in the body of dorsum sellae, and it is demonstrated by applying thin-section axial T1-weighted imaging. (Wang et al., 2018, Kurokawa et al. 1998) It was observed in 52% in adults without pituitary disease, pregnancy and lactation may result in an enlarged PBS. (Brooks et al. 1989, Bonneville et al. 2006)

Evaluating the PBS is significant in predicting pituitary abnormalities and finds cut-off values for assessing the size. The study aims to determine the dimensions of the PBS and its incidence among the normal Sudanese adults using magnetic resonance imaging.

## MATERIALS AND METHODS

This is a descriptive cross-sectional study conducted at the Radiology Department in Al Amal National Hospital and Yastabshiroon Omdurman Medical Center. The data were collected from 120 normal Sudanese adult subjects (46 males and 74 females) who underwent an MRI examination for the brain. The included criteria are normal Sudanese adults whose ages ranged between 20 to 60 years. The exclusion criteria were pituitary disease or abnormality e.g., microadenoma, macroadenoma,

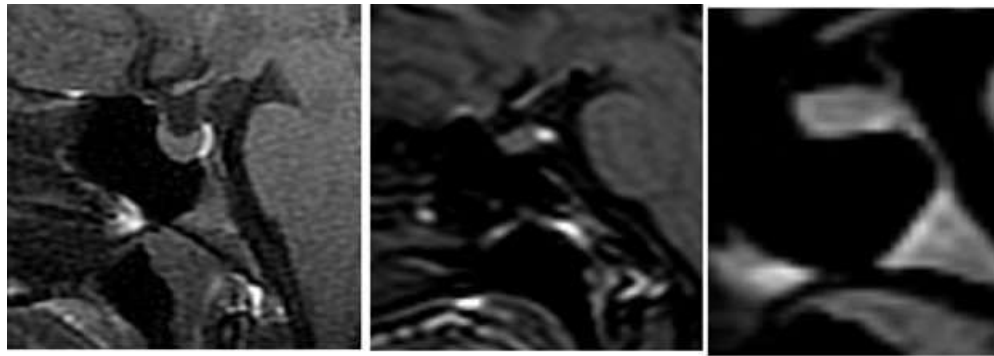
pituitary hormones disturbance, head trauma, Rathke's cleft cyst, and hemorrhagic pituitary adenomas. High T1 signal intensity in the Sella was excluded.

Ethical approval was obtained from the Department of Radiology in Ysatabshiroon Medical Center and Al Amal National Hospital, then a verbal ethical approval taken from the participant included in this study. Magnetic resonance (MR) routine examination was performed using General Electric Health Care (GE SIGNA EXCITE) with a 0.2T permanent magnet (open magnet) machine that was used in Ysatabshiroon Medical Center. Standard head coil, 512\*512 matrix size, selected field of view (FOV) was (24\*18) were used for acquiring the MR images. The sagittal and axial views were displayed using the midline plane of T1-weighted image spine-echo, and (Scan parameters were repetition time/echo time (TR/TE) of 450/10.5ms, 378/8.6ms, Slice thickness of 6.3 mm). In a 1.5 T closed magnet, Philips medical system (intera) machine was used in Al Amal National Hospital to perform the scan using body transmit coil type and sense head receive coil. T1 axial sagittal and coronal spin-echo images, coronal T2 image, and diffusion-weighted imaging (DWI) were applied. The scan parameters were repetition time/echo time (TR/TE) of 450/10.5ms and 378/8.6ms, matrix size of 256\*256, FOV was 24x18 cm, and the slice thickness was 5 mm.

The PBS appears as oval, round, and crescent with high T1 signal on the midsagittal section in the pituitary fossa (figure 1).

The images were obtained and interpreted in the long axis, short axis dimension (perpendicular to the long axis). The area of the pituitary bright spot was determined and measure also. (Figures 2 and 3).

The data were analyzed using the statistical package for social sciences (SPSS) version 23. Descriptive statistics were obtained to find the mean and frequency of the gender, age groups, and the pituitary gland. The descriptive statistics were performed to evaluate the long axis of PBS, short axis, and the area (minimum, maximum, and a mean± SD). The independent-sample t-test and one way a nova test was applied to assess whether there was a statistical difference in dot measurement in the age groups and to find the difference between the gender. The *P*-values < 0.01 or <0.05 were considered statistically significant.

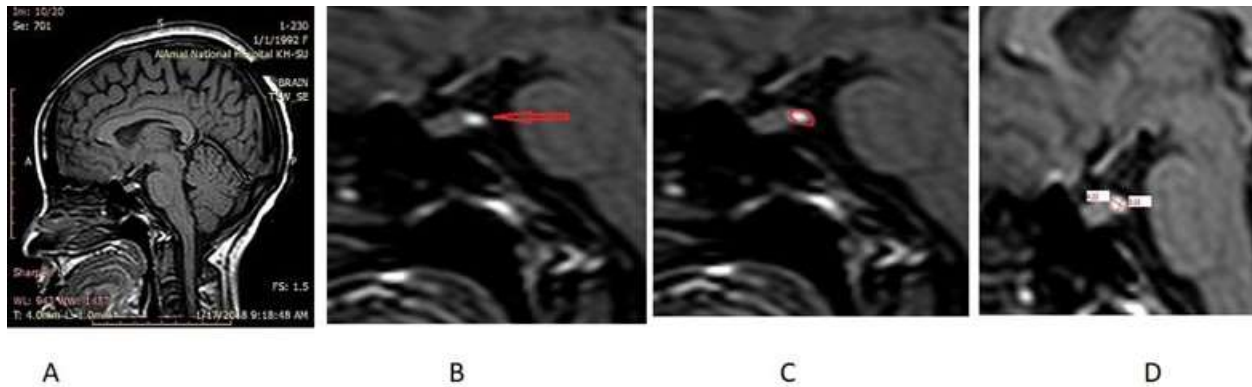


A

B

C

Figure 1: A-C Shape of PBS as seen in MRI T1 images A. crescent shape, B. oval shape, C. rounded shape



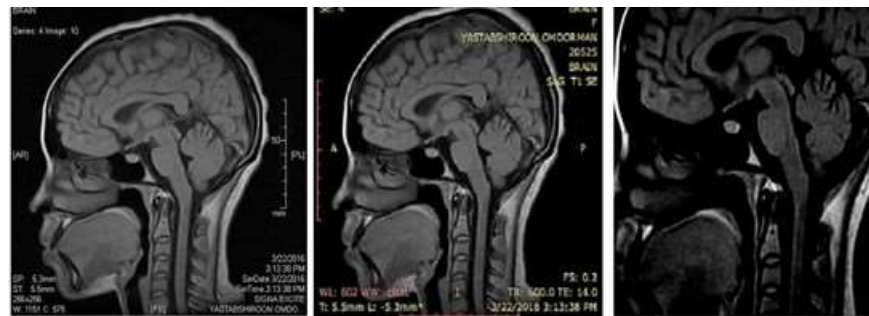
A

B

C

D

Figure 2: A-D are 1.5T midsagittal T1-weighted MR images taken without contrast enhancement in a 29-year-old woman revealing a T1-hyperintense region in the pituitary gland, red arrow). The scan parameters were TR/TE and 540 /15. The high tesla magnetic field at the edge of spot was well defined and no need to adjust window (WW1457, WL 943). C: define the area measurement. D: Long and short axis measurements.



A

B

C

Figure 3: A-C 0.2T were midsagittal T1-weighted MR images without contrast enhancement of a 49-year-old woman demonstrating a T1-hyperintense region in the pituitary Sella. The scan parameters were TR/TE and 600 /14. The low intensity magnetic field needs to manipulate the window for defining the edge of the spot

We noticed that the resolution of the PBS in the 1.5 tesla was excellent compared to 0.2 tesla which need to manipulate the windowing. As shown in figure (2,3).

**RESULTS**

This study included 120 Sudanese adults with age ranged 20-60 years , 33.3% of them in the age group 20-30 years , followed by 25.8% in age group 31-40 years, most of them were female 61.7% (74 patients), as shown in table 1.

We found that the PBS found in 65 patients (54.2%), table 2.

The study revealed that age range was 20-60 years and the mean was 38.15 years , the long axis measurement of PBS was 0.66-7.67 mm with mean of 4.50 ±1.26mm, while the short axis ranged 1.32-4.33 mm with the mean of 2.79±0.70mm. The area of PBS ranged area was 0.02- 0.36 mm<sup>2</sup> with a mean of 0.11±0.05 mm<sup>2</sup> as

shown in table 3.

The study found that there was a significant difference in mean measurements of PBS in both gender, p value < 0.001 for measurement of PBS short axis in male and female and <0.05 for measurement of PBS long axis and area in different gender. The measurement of PBS is more in male than female , the long , short axis measurement and area for male were 4.86±1.43 mm,3.03±.69 mm,.12±.05 mm respectively, while for female were 4.11±.92mm, 2.52±.63 mm and .09±.05mm<sup>2</sup> respectively. Table 4, figure 4

No significant difference in PBS Measurement in different age groups, P value> 0.05. The age group 51-60 had larger pituitary dot diameters in the long and short axes than other age groups followed by the younger age group of 20-30 years (4.83±1.70 vs. 4.48±1.30 mm, and 2.86±.70 vs.2.79±.79 mm) respectively, as shown in table 5 and figure (5).

**Table 1: Frequency distribution of age and gender**

Age group \ years	Frequency	Percent	Valid Percent	Cumulative Percent
20-30	40	33.3	33.3	33.3
31-40	31	25.8	25.8	59.2
41-50	24	20.0	20.0	79.2
51-60	25	20.8	20.8	100.0
<b>Gender</b>				
Male	46	38.3	38.3	38.3
Female	74	61.7	61.7	100.0
Total	120	100.0	100.0	

**Table 2: Frequency distribution of the presence of PBS**

Presence of PBS	Frequency	Percent	Valid Percent	Cumulative Percent
yes	65	54.2	54.2	54.2
no	55	45.8	45.8	100.0
Total	120	100.0	100.0	

**Table 3 |:Measurements of age and dimensions PBS**

Variables	Minimum	Maximum	Mean ± SD
Age \ years	20	60	38.15±13.75
Long axis of PBS \ mm	.66	7.67	4.50±1.26
Short axis of PBS \ mm	1.32	4.33	2.79±.70
Area of PBS \ mm	.02	.36	.11±.05
Valid N (listwise)			

Table 4: Independent sample t-test for compare mean measurement of PBS in different gender

Measurements	Gender	N	Mean ±Std. Deviation	Std. Error Mean	P value
Long axis of PBS \ mm	Male	34	4.86±1.43	.24	0.015*
	Female	31	4.11±.92	.16	
Short axis of PBS \ mm	Male	34	3.03±.69	.11	0.003*
	Female	31	2.52±.63	.11	
Area measurement \ mm	Male	34	.12±.05	.01	0.029*
	Female	31	.09±.05	.01	

Table 5: One way a nova for compare mean PBS measurement in different age group

Age group \years	long axis of PBS \ mm (mean ± SD)	Short axis of PBS \mm (mean ± SD)	Area measurement of PBS \mm (mean ± SD)	P value
20-30	4.48±1.30	2.79±.79	.11±.05	>0.05
31-40	4.29±.83	2.74±.64	.09±.03	
41-50	4.29±.75	2.73±.66	.12±.08	
51-60	4.83±1.70	2.86±.70	.12±.05	
Total	4.50±1.26	2.79±.70	.11±.05	

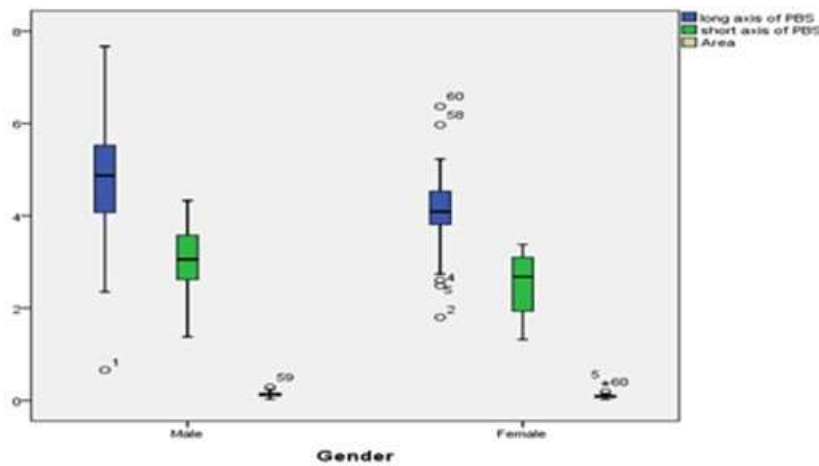


Figure 4: plot box shows mean measurements of PBS in different gender

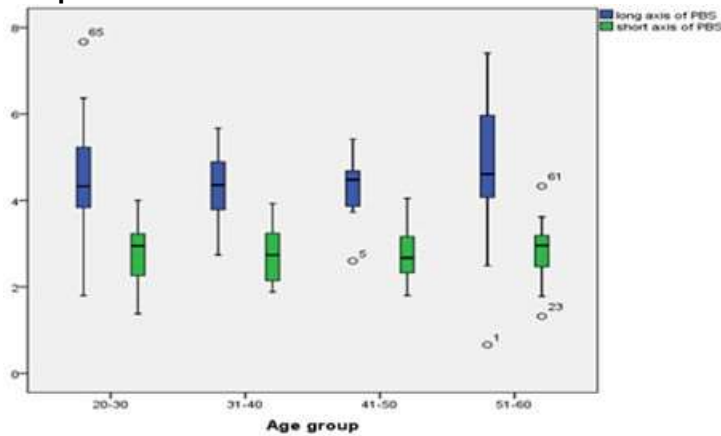


Figure 5 : plot box shows mean measurements of PBS in different age group



## DISCUSSION

The pituitary bright spot appears on T1-weighted MRI as an area of hyperintensity, and its dimensions must be in the identified normal range in the majority of subjects. This study showed that the pituitary bright spot axis was assessed using MRI sequences in Sudanese participants.

The current study revealed that the PBS is noticed in 54.2% of cases. Most of them appears at the midline sagittal sections. This finding is consistent with Wang et al. who reported that; MRI-T1 sagittal and coronal sections were used carefully to identify the posterior pituitary spot with two common locations along with pituitary stalk and in Sella. (Wang et al.2018). Brooks et al. Colombo et al and Fujisawa et al and found that the PBS occurs in 52%, 90% and 100 in normal pituitary gland population. (Brooks et al. 1989, Colombo et al. 1987, Fujisawa et al. 1987)

It was found that the dimensions of the PBS in the long axis was  $4.50.15 \pm 1.26$  mm (ranged 0.66-7.67 mm), and the short axis was  $2.79 \pm 0.70$  mm (ranged 1.32-4.33 mm). In agreement to these findings, Côté et al found that the dimensions of the PBS were  $4.8 \pm 1.2$  mm (range 1.7–7.8 mm) in the long axis and  $2.4 \pm 0.7$  mm (range 0.9–3.9 mm) in the short axis. (Côté et al., 2014)

The study found a significant difference between the long axis, short axis, and area of PBS with the gender. In contrast to this result, Côté et al found no significant relationship was found between the long-axis dimension and sex differences ( $p = 0.088$ ). (Côté et al. 2014)

The present study found that the dimensions of the PBS are higher in males than females. In contrast, this result is inconsistent with Fujisawa et al. (Fujisawa et al. 1987), who found the dimensions of PBS were more in women than men. Côté et al also observed that larger PBSs were found in females along the long axis. (Côté et al. 2014). However, the difference was not statistically significant, and the mean dimension along the short axis was 40% smaller than that of Fujisawa et al. Klyn et al. also found PBS is more commonly occurs in female. (Fujisawa et al. 1987, Klyn et al. 2018) The discrepancy in our findings might be attributed to the ethnic difference and small sample size.

The study found no significant difference in the mean PBS measurements (long axis, short axis, and area) among the different age groups,  $P > 0.05$ . It was observed that the dimensions of the long axis dimensions of the PBS increased in 51-60 years, followed by the age group of 20-30

years. Côté et al reported that the measurement decreased with age, a significant inverse linear correlation existed between the long-axis dimension and the subjects ( $p = 0.042$ ). However, there was no significant relationship existed between the long-axis dimension, short-axis dimensions, and age of the subject ( $p = 0.401$ ). (Côté et al.2014). Yamamoto et al reported that the signal intensity in posterior pituitary lobe reversely related with age in both genders. (Yamamoto, Oba and Furui, 2012)

There are many causes of the PBS in normal subjects reported in the literature. A study conducted by Côté al reported that the PBS rate decreased with advanced patient age and related to the higher plasma osmolality in older people. The change in plasma osmolality leads to increased secretion of vasopressin resulting in the disappearance of the PBS. It may become smaller when less vasopressin is stored in the posterior lobe of the pituitary gland, which leads to the reduction of the PBS size with patient age. (Côté et al.2014)

The study faced some problems as the sample size is not large enough. There are no laboratory investigations. Increasing the sample size will lead to more accuracy of measurements in terms of age, weight. And we recommend measuring the blood sugar and hormones related to these phenomena e.g., ADH (Antidiuretic Hormone), vasopressin before the examination for comparison among the subjects.

## CONCLUSION

The PBS was identifiable in 54.2% of Sudanese adults with the normal pituitary gland in unenhanced T1-weighted MRI. The measurement of the pituitary bright spot (PBS) in normal adult Sudanese individual is similar to that mentioned in the previous studies, the long axis measurement of PBS was 0.66-7.67 mm with mean of  $4.50 \pm 1.26$ mm, while the short axis ranged 1.32-4.33 mm with the mean of  $2.79 \pm 0.70$ mm. A significant difference was found in the measure of PBS in-between gender; the male had larger PBS diameters than females with a considerable difference.

## CONFLICT OF INTEREST

The authors declared that present study was performed in absence of any conflict of interest.

## FUNDING SOURCE:

The authors received no financial support for the research, authorship, and/or publication of this

article.

### ACKNOWLEDGEMENT

We would like to thank the staff working in the X-ray and MRI department in Al Amal National Hospital and Yastabshiroon Umdorman medical center for their kindness and allow us take to collect data from patients and get the required images for research, as well as to thank Dr. Khaled Abdel Moneim for help and assistance.

### AUTHOR CONTRIBUTIONS

SH design the study, SH and AC performed MRI investigation, and collected the data, AG, AI, RA and MG prepare manuscript, AG did the data analysis, MG and EA reviewed the manuscript. All authors read and approved the final version.

---

### Copyrights: © 2020@ author (s).

This is an open access article distributed under the terms of the [Creative Commons Attribution License \(CC BY 4.0\)](https://creativecommons.org/licenses/by/4.0/), which permits unrestricted use, distribution, and reproduction in any medium, provided the original author(s) and source are credited and that the original publication in this journal is cited, in accordance with accepted academic practice. No use, distribution or reproduction is permitted which does not comply with these terms.

---

### REFERENCES

Andronikou S, van Toorn R and Boerhout E (2009). MR imaging of the posterior hypophysis in children with tuberculous meningitis European Radiology, 19(9), pp. 2249 -2254.

Bonneville F, Cattin F, Marsot-Dupuch K, Dormont D , Bonneville J -F. and Chiras J (2006). T1 Signal Hyperintensity in the Sellar Region: Spectrum of Findings. RadioGraphics, 26(1), pp.93–113.

Brooks B, Gammal, T, Allison J and Hoffman W (1989). Frequency and variation of the posterior pituitary bright signal on MR images. American Journal of Roentgenology, 153(5), pp.1033–1038.

Côté M, Salzman K.L, Sorour M and Couldwell W.T (2014). Normal dimensions of the posterior pituitary bright spot on magnetic resonance imaging. Journal of Neurosurgery, 120(2), pp.357–362.

Colombo N , Berry I, Kucharczyk J , Kucharczyk W , de Groot J , Larson T , Norman D and Newton T.H (1987). Posterior pituitary

gland: appearance on MR images in normal and pathologic states. Radiology, 165(2), pp.481–485.

Fujisawa I, Asato R, Nishimura K, Togashi K, Itoh K , Nakano Y , Itoh H , Hashimoto N, Takeuchi J and Torizuka K (1987). Anterior and Posterior Lobes of the Pituitary Gland; Assessment by 1.5 T MR Imaging. Journal of Computer Assisted Tomography, 11(2), pp.214–220.

Hess C.P and Dillon W.P (2012). Imaging the Pituitary and Parasellar Region. Neurosurgery Clinics of North America, 23(4), pp.529–542.

Kilday J-P., Laughlin S, Urbach S, Bouffet E and Bartels U (2014). Diabetes insipidus in pediatric germinomas of the suprasellar region: characteristic features and significance of the pituitary bright spot. Journal of Neuro-Oncology, 121(1), pp.167–175.

Klyn V, Dekeyzer S, Van Eetvelde R, Roels P, Vergauwen O, Devolder P, Wiesmann M, Achten E and Nikoubashman O. (2018). Presence of the posterior pituitary bright spot sign on MRI in the general population: a comparison between 1.5 and 3T MRI and between 2D-T1 spin-echo- and 3D-T1 gradient-echo sequences. Pituitary, 21(4), pp.379–383.

Kurokawa H, Fujisawa I, Nakano Y, Kimura H, Akagi K, Ikeda K, Uokawa K and Tanaka Y (1998). Posterior lobe of the pituitary gland: correlation between signal intensity on T1-weighted MR images and vasopressin concentration. Radiology, 207(1), pp.79–83.

Lee M-H, Choi H-Y, Sung Y-A and Lee J-K (2001). High signal intensity of the posterior pituitary gland on T1-weighted MR images: Correlation with plasma vasopressin concentration to water deprivation. Acta Radiologica, 42(2), pp.129–134.

Wang S, Lin K, Xiao D, Wei L and Zhao L (2018). The Relationship Between Posterior Pituitary Bright Spot on Magnetic Resonance Imaging (MRI) and Postoperative Diabetes Insipidus for Pituitary Adenoma Patients. Medical Science Monitor, 24, pp.6579–6586.

Yamamoto A, Oba H and Furui S(2012). Influence of age and sex on signal intensities of the posterior lobe of the pituitary gland on T1-weighted images from 3 T MRI. Japanese Journal of Radiology, 31(3), pp.186–191.