

Effects of chronic administration of efavirenz on the deoxyribonucleic acid (DNA) of the intracranial auditory relay centres of adult wistar rats.

J.O. Adjene* and P.S. Igbigbi

Department of Anatomy and Cell Biology, Faculty of Basic Medical Sciences, College of Health Sciences, Delta State University, Abraka, Delta State, **Nigeria.**

*Corresponding author

The effects of chronic administration of efavirenz commonly used as part of highly active antiretroviral therapy (HAART) for the treatment of Human Immunodeficiency Virus (HIV) type-1 therapy on the DNA of the intracranial auditory relay centre namely the inferior colliculus and medial geniculate body of adult wistar rats were carefully studied. The rats of both sexes (n=20), with an average weight of 200g were randomly assigned into treatment (n=10) and control (n=10) groups. The rats in the treatment group received 600mg/70kg body weight of efavirenz dissolved in distilled water daily for 30 days through the orogastric tube. The control group received equal volume of distilled water daily for 30 days through the same route. The rats were fed with grower's mash obtained from Edo Feeds and Flour Mill Limited, Ewu, Edo state, Nigeria and given water liberally. The rats were sacrificed by cervical dislocation method on the thirty-first day of the experiment. The inferior colliculus and medial geniculate body were carefully dissected out and quickly fixed in 10% formal saline for histochemical study. The histochemical findings indicated that the treated sections of the inferior colliculus and medial geniculate body showed less intense staining and appearing pachychromatic. The stained neurons and glia cells were few as compared to the control sections. There were observations of neuronal enlargement in the inferior colliculus and medial geniculate body of the treated sections. The inferior colliculus of the treated group showed evidence of hypertrophy and microcytic changes in the darkly stained DNA positive granules, while the treated section of the medial geniculate body showed positively stained DNA granules of various sizes and shapes, with an indication of hypertrophy and microcytic changes as compared to the control group. Chronic administration of efavirenz may therefore have an adverse effect on the DNA of the inferior colliculus and medial geniculate body of adult wistar rats. It is recommended that further studies aimed at corroborating these observations be carried out.

Key words: Efavirenz, DNA, Inferior Colliculus, Medial Geniculate Body, Wistar Rats.

Efavirenz is an antiretroviral drug that belongs to the class of drugs called non-nucleoside reverse transcriptase inhibitor (NNRTI) used as part of highly active antiretroviral therapy (HAART) for the treatment of human immunodeficiency virus (HIV) type-1 (AHFS, 2007). Efavirenz has been found to be effective in many combination regimes for the treatment of HIV infection, both in previously untreated and in treated individuals. It has been combined successfully with nucleoside consisting of lamivudine or emtricitabine plus

abacavir, didanosine, stavidine, tenofovir or zidovudine to achieve virologic suppression in a high percentage of recipients (Staszewski et al., 1999; Gulick et al., 2006). Most antiviral agents do not efficiently penetrate the blood brain barrier (BBB) or are actively transported out of the central nervous system (Schranger, and D'Souza, 1998). Even after antiviral treatment that successfully controls virus in the treatment compartments, the central nervous system may suffer continuing damage induced by HIV infection (Fox et al.,

2000). Efavirenz may be taken once a day without regards to meal and it can penetrate the central nervous system and spinal fluids (AIDS INFONET, 2007; Puzantian, 2002)

Some adverse effect in the central nervous system has been commonly associated with efavirenz (Ruiz et al., 1999). The most common central nervous system effects include confusion, insomnia, abnormal vivid dreams, dizziness and headache. Efavirenz has emerged as cornerstone of highly active antiretroviral therapy (HAART) regimens. The side effect profile of the drug is generally regarded as satisfactory. However, there are conflicting study results in the medical literature as well as conflicting studies from patients and physicians regarding the neuropsychiatric problems associated with efavirenz (Baker, 2006). Lipodystrophy, moderate or severe pain, abnormal vision, arthralgia, asthenia, dyspnea, gynecomastia, myalgia, myopathy and tinnitus have been reported concerning efavirenz (AHFS, 2007).

The inferior colliculus and medial geniculate body constitutes the intracranial auditory relay centres. The inferior colliculus is the obligatory midbrain synaptic target of the ascending auditory pathway, in which the contralateral ear is represented primarily (Fall, 1999). Inferior colliculus is essential for normal hearing and for the startle reflex. It receives its ascending input mainly from the contralateral cochlear nucleus and the superior olive and sends axons to the medial geniculate body (Fall, 1999). The medial geniculate body is the target of ascending projection from the inferior colliculus and descending input from the auditory cortex this is the obligatory synaptic target in the thalamus for hearing (Fall, 1999). It contains interleaved and overlapping tonotopic and aural bands, the most beautiful structure in the brain (Fall, 1999). The cerebral cortex strongly affects the medial geniculate body through descending projections. These projections were thought to consist primarily of small areas with slow conduction velocities (Winer *et al.*, 1996). It has been demonstrated that neurons of auditory cortex showed great physiological plasticity when rats were exposed to specific stimuli coupled with concurrent stimulation of a forebrain subcortical structure in the nucleus basalis. Changes include massive expansion of frequency-specific representation (Winer *et al.*, 1999). Cortical structures such as the

medial and lateral geniculate bodies, inferior and superior colliculi have higher glucose utilization than other structures (Siesjo, 1978). There is a correlation between functional activity and metabolic rate such as in the visual and auditory system (Siesjo, 1978). Since efavirenz crosses the blood brain barrier, it is relevant to investigate its histochemical effect on the inferior colliculus and medial geniculate body. It is probable that the adverse effects of efavirenz on hearing such as tinnitus may be due to direct effect of efavirenz on the inferior colliculus and medial geniculate body. Neuronal and glia cells showed the presence of deoxyribonucleic acid (DNA), which are the transmitters of genetic information. The DNA is also involved in protein synthesis where information stored in them is transferred to RNA. Feulgen reaction specifically stained nuclear chromatin; the aldehyde liberated during hydrolysis is from the deoxypentose but not from ribose. The integrity of nuclear DNA is one of the most extensively used biochemical markers for cell death (Cohen and Yielding, 1965). This present study was to elucidate the biochemical effects of chronic administration of efavirenz on the DNA of the intracranial auditory relay centre of adult wistar rats.

MATERIALS AND METHODS

Animals: The School of Basic Medical Sciences, University of Benin grant approval before the work began. Twenty adult wistar rats of both sexes with average weight of 200g were randomly assigned into two groups; control (n=10) and treatment (n=10). The rats were obtained and maintained in the Animal Holding of the Department of Anatomy, School of Basic Medical Sciences, University of Benin, Benin City, Edo State, Nigeria. They were fed with grower's mash obtained from Edo Feeds and Flour Mill Limited, Ewu, Edo State, Nigeria and given water liberally. Efavirenz was obtained from the President Emergency Plan for AIDS Relief (PEPFAR) Unit, University of Benin Teaching Hospital, Benin City, Edo State, Nigeria.

Drug Administration: The rats in the treatment group received the recommended dosage of 600mg/70kg body weight of efavirenz dissolved in distilled water for thirty days through orogastric tube administration while the control rats received equal volume

of distilled water through the same route and for the same period. The rats were sacrificed by cervical dislocation on the thirty-first day of the experiment. The skulls were opened using bone forceps to expose the brain of the rats and the inferior colliculus and medial geniculate body were quickly dissected out and fixed in 10% formal saline for DNA staining techniques.

Histochemical Study: The tissues were dehydrated in an ascending grade of alcohol (ethanol), cleared in xylene and embedded in paraffin wax. Serial sections of 6 microns thick were obtained using a rotatory microtome. The deparaffused sections were stained routinely for DNA using Feulgen and Rosenbach (1924) staining procedures. The sections were then rinse in distilled water, dehydrated through ascending grades of alcohol, cleared in xylene and mounted in DPX for DNA observation. The photomicrographs of the desired results were obtained using research photographic microscope in the Department of Anatomy, School of Basic Medical Sciences, University of Benin, Benin City, Edo State, Nigeria.

RESULTS

The control sections of the inferior colliculus and medial geniculate body stained deep magenta colour. The stained nuclei were numerous and did not appear enlarged. The nuclei were distinct and widely distributed (plates 1A and 2A).

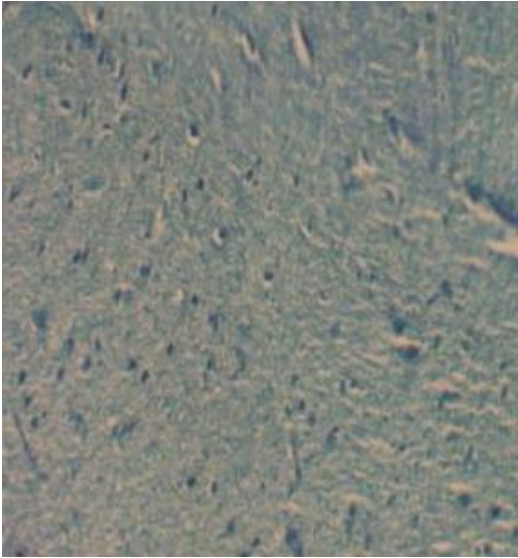
The treatment sections of the inferior colliculus and medial geniculate body showed less intense staining and appearing pachychromatic. The stained neurons and glia were few when compared to the control sections. There were observations of neuronal enlargement in both the inferior colliculus and medial geniculate body of the treated sections (plates 1B and 2B). The treated section of the inferior colliculus showed evidence of hypertrophy as indicated by enlarged darkly stained DNA positive granules with some microcytic changes and less intensity (Plate 1B), while the treated section of the medial geniculate body showed scanty positively stained DNA granules of varying sizes and shapes (Plate 2B)

DISCUSSION

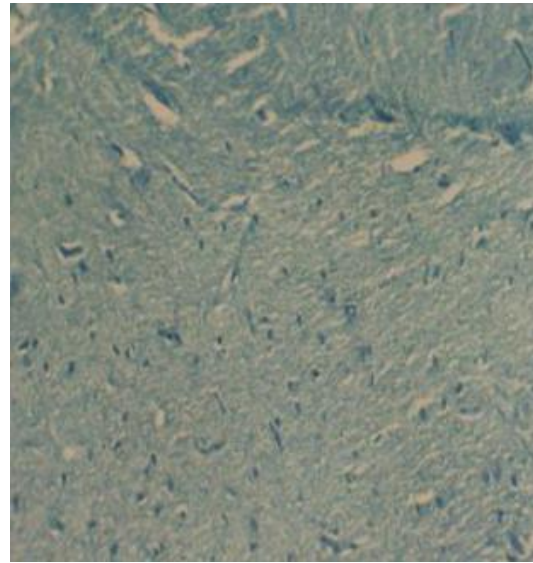
The treatment sections of the inferior colliculus and medial geniculate body showed

less intense staining and appearing pachychromatic. The stained neurons and glia were few when compared to the control sections. There were observations of neuronal enlargement in both the inferior colliculus and medial geniculate body of the treated sections. The treated section of inferior colliculus showed evidence of hypertrophy as indicated by enlarged darkly stained DNA positive granules with some microcytic changes and less intensity, while the treated section of the medial geniculate body showed scanty positively stained DNA granules of varying sizes and shapes. Neurons and glia cells showed the presence of deoxyribonucleic acid, which are the transmitters of genetic information. The DNA is also involved in protein synthesis where information stored in them is transferred to ribonucleic acid. The neurons are differentiated from glia by the presence of a large sized nucleus, which stained more intensely. Feulgen reaction specifically stained nuclear chromatin; the aldehyde liberated during hydrolysis is from deoxypentose but not from ribose. DNA is important for normal maintenance of cellular integrity. Chloroquine acts on cell sites by binding to deoxyribonucleic acid (DNA), ribonucleic acid (RNA) and proteins. This binding alters the biological and physiological characteristics of DNA helix (Cohen and Yielding 1965). It has been reported that chronic administration of efavirenz in adult wistar rats resulted in some cellular degenerative changes such as sparse cellular population, hypertrophy, microcytic changes, and vacuolation in the stroma of the treated inferior colliculus as compared to the control group (Adjene and Igbigbi, 2010). In this study efavirenz administration was observed to affect the staining intensity of nuclei in the neurons and glia cells of the inferior colliculus and medial geniculate body. The cells that stained following efavirenz administration had enlarge darkly stained nuclei and some microcytic changes among others. The enlarged darkly stained DNA granules may indicate possible adverse effects of efavirenz on DNA integrity. Chloroquine has been reported to cause complete inhibition of DNA synthesis (Cohen and Yielding 1965) and interferes with protein synthesis through the inhibition of DNA replication (Amenta *et al.*, 1978, Seglen *et al.*, 1979, Crab *et al.*, 1980). It is probable that efavirenz interference in this

A




Control section of IC x100

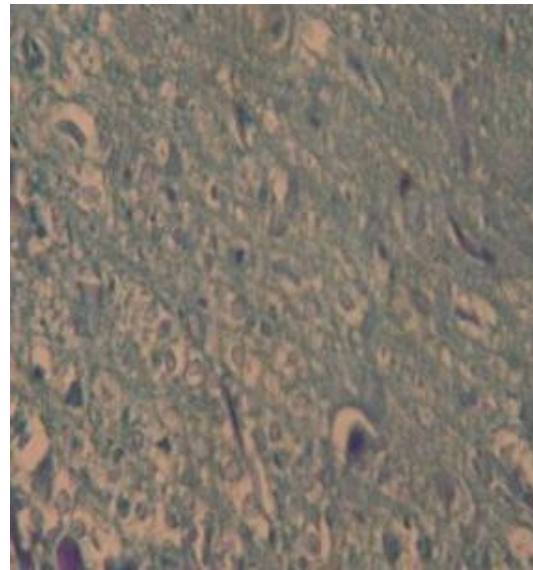


Control section of IC x400

B




Treated section of IC x100



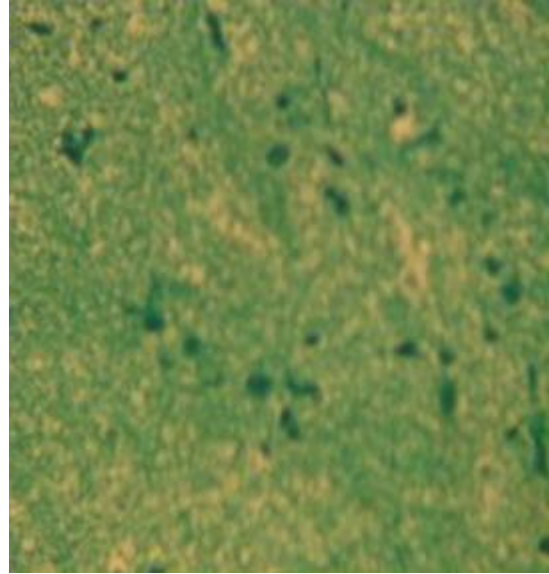
Treated section of IC x400

Plate 1: Deoxyribonucleic acid (DNA) in the inferior colliculus (IC) (Feulgen Method)

A

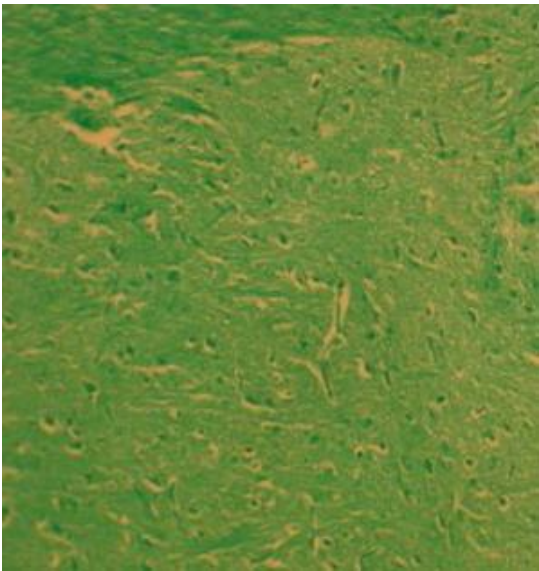


Control section of MGB x100




Control section of MGB x400

B



Treated section of MGB x100



Treated section of MGB x400

Plate 2: Deoxyribonucleic acid (DNA) in the medial geniculate body (MGB) (Feulgen method)

experiment might be the probable cause of the hypertrophied DNA granules and microcytic changes observed in this experiment. Nuclei hypertrophy leads to cell death, which may underscore the reduction in cellular density and staining intensity following treatment with efavirenz. In this study, the toxic effect of efavirenz on DNA was revealed by the less staining intensity observed in the treatment group. These effects could obviously affect the integrity and competence of the intracranial auditory relay centre in regard to their activities mediated in auditory sensibilities.

Conclusion: In this experiment, the DNA staining revealed that efavirenz administration affect the staining intensity of nuclei in the neurons and glia cells of the inferior colliculus and medial geniculate body in the treated adult wistar rats. The cells had enlarged darkly stained DNA granules with some microcytic changes and a characteristic vacuolations in the parenchyma of the inferior colliculus and medial geniculate body among others in the treated sections of the DNA as compared to the control.

REFERENCES

- Adjene, J.O and Igbigbi, P.S. 2010. Effects of chronic administration of efavirenz on inferior colliculus of adult Wistar rats. *Fooyin J. Health Sci.* 2(2-3): 105 -108.
- AIDS INFONET. 2007. Efavirenz (Sustiva) Fact Sheet; 432.
- Amenta, J.S, Hilvko, T.J, Mcbee, A.G, Shinozuka, H and Brochner, S. 1978. Specific inhibition by ammonium Chloride of autophagy associated proteolysis in cultured fibroblast. *Experimental CellResearch*, USA. 115:357
- American Hospital Formulary Service (AHFS). 2007. *Drug Information*. 86-694.
- Baker R, 2006. Central nervous system toxicities and efavirenz. Available at www.hivandhepatitis.com (Date accessed: June 22 2008).
- Cohen, S.N and Yielding, K.L. 1965. Actions of chloroquine. *Proceeding of National Academy of Sciences*. USA, 54:521.
- Crab, D. W, Jerslid, R. A, Mecure, S. A, Swartzentruber, M. S, and Harvis, R. A, 1980. Inhibition of Hepatocyte Proteolysis and Lactate in Chloroquine. *Archives of Biochemistry and Biophysics*. Great Britain. 203(1): 49.
- Fall, B 1999. *Mammalian Neuroanatomy MCB 163: Mammaalian neuroanatomy*.
- Feulgen, R and Rossenbeck, H. 1924. *Z. Physiol. Chem.* 135, 203. Fox, H.S, Weed, M.R, Resindiz S.H, Baig, J, Horn, F.W, Dailey, P.J, Bischofberger, N, Henriksen, S.J. 2000: Antiviral treatment normalizes Neurophcological but not movement abnormalities in Simian immunodeficiency virus infected monkeys. *Journal of Clinical Investigation*. Vol. 106 (37).
- Gulick, R.M, Ribaud, H.J, Shikuma, C. M. 2006. Three versus Four-Drug Antiretroviral regimens for the initial treatment of HIV-1 infection: A randomized controlled trial. *JAMA*. 296(7): 769-781.
- Puzantian, T. 2002. Central Nervous System adverse effect with efavirenz case report and review. *Pharmacotherapy*. 22(7): 930-933.
- Ruiz, N.M, Bessen, L. J, Manion, D.J. 1999. Potential adverse experiences associated with efavirenz (Sustiva in Adults). For the Efavirenz Clinical Development Team. Presented at the 6th Conference on Retrovirus and Opportunistic Infections, Chicago, IL.
- Schranger, L.K, D'Souza, M.P.1998. Cellular and Anatomical Reservoirs of HIV-1 in patient receiving potent antiretroviral combination therapy. *JAMA*. 280:67-71.
- Seglen, P.O, Carinde, B and Solhein, A.E. 1979. Inhibition of the Lysosomal Pathway of Protein Degradation in Isolated Rat Hepatocytes by Ammonia, Methylamine Chloroquine and Leupelin. *European Journal of Biochemistry*.UK, 94:215-225.
- Siesjo, B. K.1978. *Utilization of Substrates by Brain Tissues*. Brain energy metabolism. John Wiley and Sons. USA 101-130.
- Staszewski, S, Miller, V, Sabin, C, Schlecht, C, Gute, P, Stamm, S, Leder, T, Berger, A, Weidemann, E, Hill, A, Philips, A. 1999. Determinant of sustainable CD4 Lymphocyte count increases in response to response to Antiretroviral Therapy. *AIDS*. 13: 951-956.
- Winer, J. A, Larue, D. T and Huang, C. L. 1999. Cortical influence on the medial geniculate body. *J. Comp. Neurol*, 413: 181-197.

Winer, J. A, Saint Marie, R. L, Larue, D. T and Oliver, D. L.1996. The cerebral cortex strongly affects the medial geniculate body through descending projections. Proc. Nati. Acad. Sci. U.S.A. 93: 8005-8010.